



## Case report

## Lung herniation after positive pressure ventilation

Ser Hon Puah<sup>\*</sup>, Carmen Tan Pei Sze, John Abisheganaden

Department of Respiratory and Critical Care Medicine, Tan Tock Seng Hospital, Singapore 308433, Singapore

## ARTICLE INFO

## Article history:

Received 10 December 2015

Accepted 16 December 2016

## Keywords:

Lung herniation

Positive pressure ventilation

Myasthenia gravis

Thoracotomy

## ABSTRACT

Lung herniation is a rare condition which has only been mainly published as case reports in the literature. Although its description has been around since 1845, not much is still known about it. More often seen after trauma or as a surgical complication post thoracic surgery, its management usually depends on its etiology and varies between individuals. We report a case of lung herniation after positive pressure ventilation from a previous thoracotomy site. To our knowledge, this is the first report where the lung herniation was precipitated by mechanical ventilation.

© 2016 The Authors. Published by Elsevier Ltd. This is an open access article under the CC BY-NC-ND license (<http://creativecommons.org/licenses/by-nc-nd/4.0/>).

## 1. Introduction

Herniation of the lung is an uncommon entity which has only been reported mainly as case reports around the world. It is defined as a protrusion of lung tissue beyond the confines of the thoracic cavity through an abnormal opening in the chest wall, diaphragm or mediastinum lined by pleura [1]. Lung herniation was first described in 1845 by Morel-Lavallée who studied 32 cases and classified them based on anatomy and etiology [2]. Congenital causes can be from rib or intercostals hypoplasia or agenesis at a frequency of 18%. Traumatic from blunt or penetrating injury and spontaneous herniation was reported at 52% and 30% respectively for the acquired herniations [3].

## 1.1. Case report

We present a case of an 83 year old gentleman who had a history of Myasthenia gravis which was controlled on a regular dose of pyridostigmine. He also had a history of a previous left thoracotomy in 2003 after a failed video-assisted thoracoscopic surgery (VATS) for a resection of a pulmonary nodule which was eventually found to be a cryptococcoma. This was subsequently treated and his human immunodeficiency virus (HIV) screen was negative. He had an admission 4 months prior for an exacerbation for his myasthenia crisis and required non-invasive ventilation. He was subsequently placed on a tapering dose of oral prednisolone.

He presented to the hospital this time with progressive weakness over the past week with a history of cough and breathlessness which was associated with some yellowish sputum. Physical examination revealed bilateral ptosis with generalized weakness Medical Research Council (MRC) power of 4 on all limbs and neck flexion. He was given oxygen supplementation via a nasal cannula with a flow rate of 2 L/min to maintain an oxygen saturation of 95%. The respiratory examination revealed a left thoracotomy scar with decreased breath sounds on auscultation over the left lower zone of his chest. He progressed into type 2 respiratory failure and was immediately intubated and placed on invasive mechanical ventilation.

He received intravenous immunoglobulin therapy along with systemic corticosteroids. While receiving invasive mechanical ventilation, he developed recurrent mucous plugging causing lung collapses. A computed topography (CT) of the thorax was performed and he was found to have a herniation of the left lung along the posterolateral aspect of the left 7th intercostal space. This was not seen in a previous CT done in 2013 (Fig. 1).

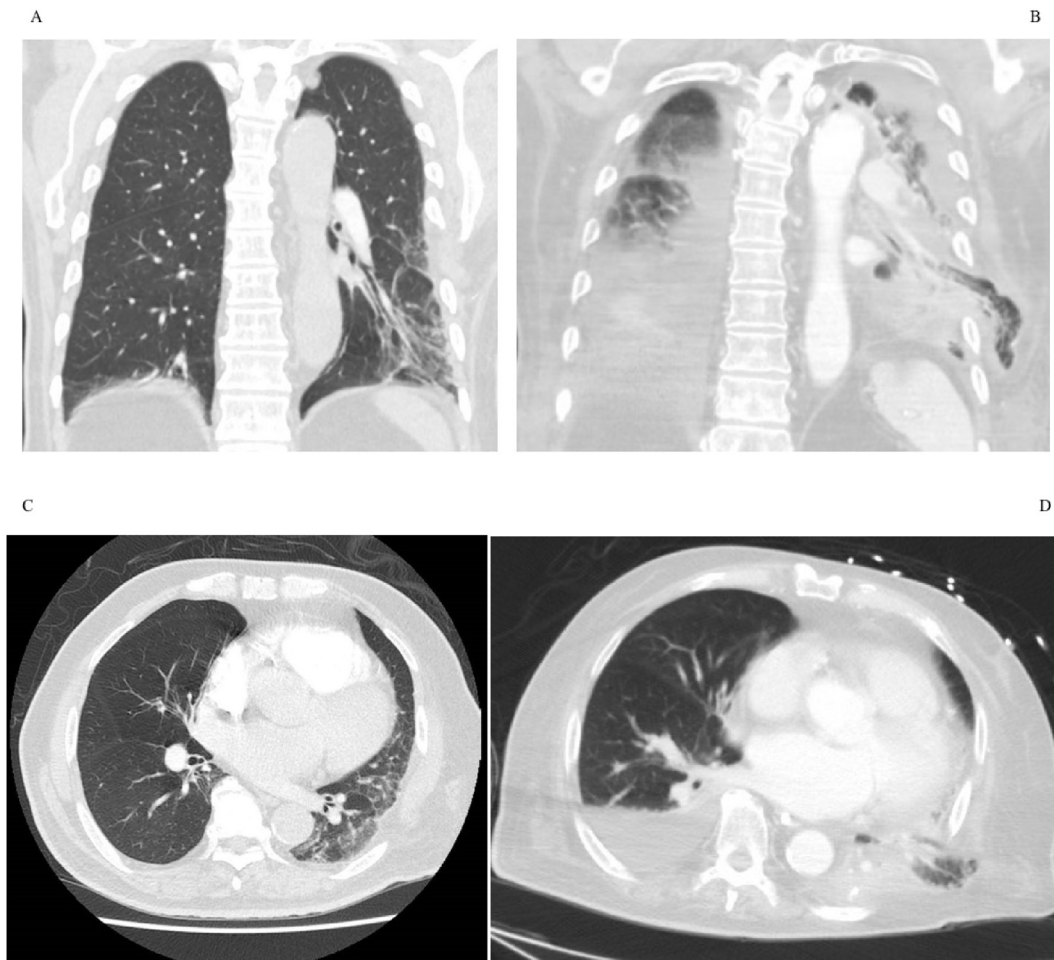
He was treated conservatively and was eventually weaned back to oxygen delivered via nasal cannula after 6 days of mechanical ventilation. He is currently asymptomatic. The examination of his respiratory system remains unremarkable at the previous thoracotomy site.

## 2. Discussion

Lung herniations are usually asymptomatic. Clinical examination may reveal a spongy bulging mass protruding over the site of herniation which is usually non tender. It may become more obvious on valsalva manoeuvre due to an increased in intrathoracic

<sup>\*</sup> Corresponding author. Tan Tock Seng Hospital, Department of Respiratory and Critical Care Medicine, 11 Jalan Tan Tock Seng, Singapore 308433, Singapore.

E-mail address: [ser\\_hon\\_puah@ttsh.com.sg](mailto:ser_hon_puah@ttsh.com.sg) (S.H. Puah).



**Fig. 1.** The coronal and axial view of the CT thorax in 2013 (A and C) showing just the residual scarring from the lobectomy and the CT thorax after positive pressure ventilation showing the left lower lung herniation (B and D).

pressure [4,5]. Occasionally, a surgical scar may be the only clue to the origin of the herniation. Traumatic hernias may appear immediately after injury and some can only be seen after some years [3].

A plain chest radiograph may be able to detect subtle changes. If suspicion is there, a CT scan should be performed to confirm and outline the anatomy of the herniation. It will also be useful to look for evidence of strangulation which would require urgent intervention. Some herniations can be demonstrated very clearly with a sagittal or coronal reformats and volume rendered three dimensional reconstruction, giving an overview of the chest for assessment of the extent of the disease and also for surgical planning [6].

Management needs to be individualised as there is no consensus on the management for lung herniation, although treatment is seldom needed as complications are rare [7]. Patient will likely only require intervention if there are recurrent symptoms, particularly pain, chest infections and evidence of incarceration [4]. In essence, surgical repair, when needed, would involve bringing the ribs together and removal of the hernia sac and non viable lung tissue. A prosthetic patch is required if the thoracic wall defect is large [8]. The conservative approach will require regular follow up with interval radiographic follow-up [9].

Our patient's lung likely herniated through the previous thoracotomy site after mechanical ventilation from a weakened intercostal muscle after increasing the intrathoracic pressure with

positive pressure ventilation [10]. Interestingly, it was reported that intercostal protrusions of the lung are more common from less extensive surgical procedures, such as VATS, as the larger surgical procedures require more meticulous forms of closure [5]. To our knowledge, this is the first case of lung herniation after positive pressure ventilation which was treated conservatively. This case illustrates how positive pressure ventilation can precipitate the herniation of the lung through a previous defect in the thoracic wall and there should be a level of clinical suspicion.

#### Conflict of interest

No conflict of interest to declare.

#### References

- [1] A.T. Donato, F.A. Hipona, S. Navani, Spontaneous lung hernia, *Chest* 64 (2) (1973 Aug) 254–256.
- [2] Morel-Lavallée *Hernies du poumon*, *Bull. Soc. Chir. Paris* 1 (1845–1847) 75–195.
- [3] F. Forty, F.C. Wells, Traumatic intercostal pulmonary hernia, *Ann. Thorac. Surg.* 49 (1990) 670–671.
- [4] C. Glenn, W. Bonekat, A. Cua, D. Chapman, R. McFall, Lung hernia, *Am. J. Emerg. Med.* 15 (1997) 260–262.
- [5] D. Weissberg, Y. Refaely, Hernia of the lung, *Ann. Thorac. Surg.* 74 (2002) 1963–1966.
- [6] A.J. Clark, N. Hughes, F. Chisti, Traumatic extrathoracic lung herniation, *Br. J. Radiol.* 82 (976) (2009 Apr) e82–e84.

- [7] J. Gonzalez, C. Cunha, Cervical lung herniation associated with upper airway obstruction, *Ann. Emerg. Med.* 19 (1990) 935–937.
- [8] M. Patel, J. Nathan, D. Frush, H. Rice, Nonoperative management of asymptomatic traumatic pulmonary hernia in a young child, *J. Trauma* 62 (2007) 234–235.
- [9] B. Francois, A. Desachy, E. Cornu, E. Ostyn, L. Niquet, P. Vignon, Traumatic pulmonary hernia: surgical versus conservative management, *J. Trauma* 44 (1998) 217–219.
- [10] E.E. Detorakis, E. Androulidakis, Intercostal lung herniation – the role of imaging, *J. Radiol. Case Rep.* 8 (4) (2014 Apr) 16–24.