



Case report

An unusual cause of ventilatory failure in motor neurone disease



Epaminondas Markos Valsamis, MB BChir, MA (Cantab), MRCS^{*},
Ian Smith, BA (Hons), MA, MBBS, MRCP, MD, Adri De Sousa, BSc

Papworth Hospital NHS Foundation Trust, Cambridge, UK

ARTICLE INFO

Article history:

Received 1 August 2016
Received in revised form
9 March 2017
Accepted 19 March 2017

Keywords:

Motor neurone disease
Respiratory failure
Parenteral feeding

ABSTRACT

A patient previously diagnosed with motor neurone disease (MND) and gastrostomy-fed was under surveillance for ventilatory decline via our respiratory centre. At a planned review she was found to be hypercapnic, which would usually prompt an offer of non-invasive ventilation for home use. However, she was alkalotic and not acidotic as we might expect. Her serum potassium was checked urgently and confirmed as low. It was established that the community team had prescribed a feeding regime with insufficient potassium. Correction of hypokalaemia resolved her ventilatory failure. This case demonstrates the importance of co-ordinated care in the management of patients with MND.

© 2017 The Authors. Published by Elsevier Ltd. This is an open access article under the CC BY-NC-ND license (<http://creativecommons.org/licenses/by-nc-nd/4.0/>).

1. Background

Respiratory failure is the most frequent cause of death in people with MND. It may present with sleep disturbance, dyspnoea and orthopnoea but can be asymptomatic and so surveillance has been recommended [1]. Randomised, controlled trial evidence confirms that non-invasive ventilation (NIV) can effectively treat ventilatory failure improving quality of life and prognosis [2]. Expert multi-disciplinary team (MDT) input is associated with improved survival in patients with MND [3]. However, in this patient's case, the cause of an elevated PaCO₂ was not progression of MND and NIV was not the answer. A full MDT review of her care produced a favourable outcome.

2. Case presentation

A 70 year old woman presented to her general practitioner in December 2013 with dysarthria and was diagnosed with amyotrophic lateral sclerosis-type MND in September 2014 following neurology review. Her swallow deteriorated and she had a percutaneous endoscopic gastrostomy (PEG) feeding tube placed in early 2015. Over time she became dependant on this for all of her nutrition and also developed anarthria.

The neurology team referred her to our respiratory centre. Spirometric values were not reliable due to an inadequate seal with

a mouthpiece. Her sniff nasal inspiratory pressure was low, recorded at −19cm H₂O. Overnight oximetry, self-ventilating on air, showed a slightly low mean O₂ saturation at 91%. Arterial blood gas (ABG) measurement showed normal values, see Table 1 below (1), and we initiated 3-monthly follow up as surveillance for deterioration (2).

During a regular respiratory review, she reported increased shortness of breath, episodes of collapse and weaker legs. Her ABG (3) self ventilating on room air showed ventilatory failure but unexpectedly she had an alkalosis. She had marked hypokalaemia (K⁺ 1.9) while other electrolytes including magnesium were normal. An ECG showed no abnormality. She was treated urgently with intravenous and PEG-potassium replacement and improved with normalisation of the ABG (4) and resolution of her dyspnoea, demonstrating the cause was hypokalaemia and not progression of her MND: see Fig. 1.

Our dietician reassessed the feeding regime initiated in the community and found her potassium intake was just 28 mmol/day, considerably below the expected requirement of around 50mmol/day for her weight of 53.4kg. The patient did not wish to switch to a continuous enteral feed so she remained on boluses, which were increased in frequency from 3 to 5 per day and the patient was allowed home.

Two weeks later she was reviewed and reported recurrent dyspnoea and her ABG (5) again showed ventilatory failure associated with hypokalaemia. She had not been able to tolerate the more frequent bolus feeds due to bloating and diarrhoea. She had a further course of potassium supplements and agreed to a continuous enteral feed regime, which she was able to tolerate.

^{*} Corresponding author.

E-mail address: markosvalsamis@gmail.com (E.M. Valsamis).

Table 1
Arterial blood gas results, self-ventilating on room air.

		pH	PaCO ₂ (kPa)	PaO ₂ (kPa)	HCO ₃ ⁻ (mmol/l)	K ⁺ (mmol/l)
1	Baseline 2014	7.41	5.08	13.36	23.7	3.91
2	September 2015	7.40	5.84	11.1	26.3	3.81
3	Index admission	7.52	7.0	9.5	41.5	1.90
4	K ⁺ replacement	7.48	5.6	9.8	30.5	3.42
5	Readmission	7.48	6.7	10.0	36.2	2.37
6	K ⁺ replacement	7.45	5.9	10.7	29.8	4.06

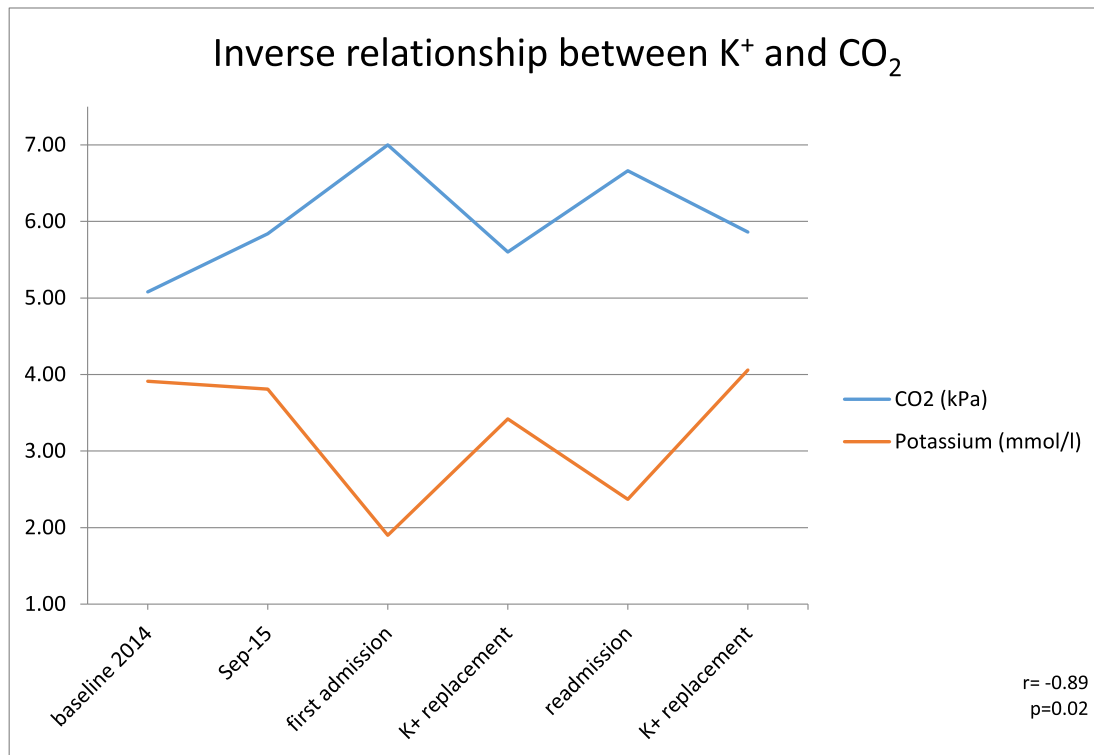


Fig. 1. Arterial blood gas potassium and PaCO₂ measurements in our patient at different points in her management. Using Pearson's correlation coefficient $r = -0.89$, ($p = 0.02$).

3. Discussion

MND spares eye movements but otherwise can affect all voluntary muscle systems. The pattern of involvement and rate of progression is individual to each patient but can lead to serious impairment in mobility, ability to self-care, speech, swallowing and ventilation. The condition is best managed with a multidisciplinary approach [3]. PEG-feeding is a well-established method of ensuring adequate nutrition and reduces the risk of aspiration in MND patients with predominantly bulbar symptoms [1]. NIV may be considered when vital capacity falls below 50% of that predicted when there are symptoms, but certainly when PaCO₂ rises above 6kPa [1]. At this stage we would usually expect to see an actual or a compensated respiratory acidosis.

Hypokalaemia induces increased ammonia excretion from the kidney and leads to a metabolic alkalosis [4]. The alkalosis can lead to a reduction in ventilatory drive that produces, as in this case, partial respiratory compensation with a raised PaCO₂. This effect has been reported in a series of patients with alkalosis, not all of whom were hypokalaemic (Feldman et al.) [5]. Our patient consistently reported dyspnoea when hypercapnic, which would not be anticipated if respiratory drive was reduced and might suggest respiratory muscle weakness due to hypokalaemia.

However, her ABG results fall neatly on the line of best fit for the data of Feldman et al. [5] when comparing to their normokalaemic patients (see Fig. 2 below). This suggests a common mechanism with this group of patients: hypokalaemia-induced metabolic alkalosis (with respiratory compensation), and no direct effect of hypokalaemia on ventilator muscle strength (see Fig. 2 below). Further, respiratory muscle weakness has been reported with profound hypokalaemia but would be expected to lead to a respiratory acidosis not alkalosis [6–9]. Dyspnoea has previously been reported with respiratory alkalosis [10].

The patient has had weekly follow-up in the community and is doing well with no more episodes of hypokalaemia or shortness of breath. She has remained free of ventilator failure two months on from the last episode of hypokalaemia.

4. Learning points

- Hypokalaemia can have such a profound metabolic consequences on pH as to suppress ventilation (as well as directly causing respiratory muscle weakness)
- Always systematically assess alternative causes for a patient's presentation prior to management. Treating this patient's symptoms with NIV may have delayed recognition of her severe

Goodness of fit of our patient's data on Feldman's normokalaemic patients

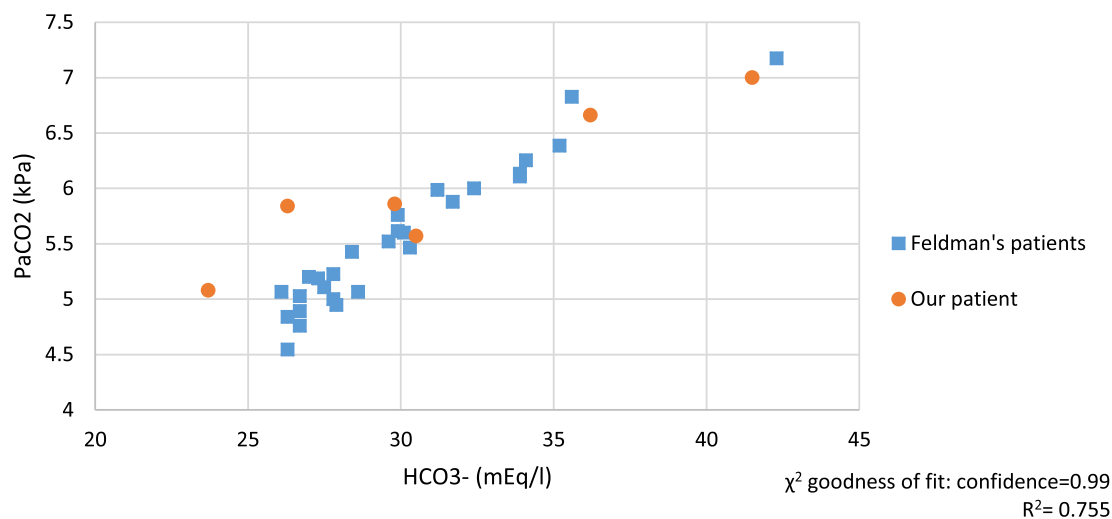


Fig. 2. Comparison of our patient's ABG results with those from Feldman's normokalaemic patients. The goodness of fit was assessed with a chi-squared test and our values were found to be near-perfectly fitting with confidence 0.99. Permission to reproduce data from Feldman et al. [5] has been granted by Dustri-Verlag journal.

hypokalaemia and treating symptoms of dyspnoea without checking blood gas status may have left her dangerously at risk of cardiac complications.

- A multidisciplinary approach with dieticians is key to managing feeding-related issues

References

- [1] NICE Guideline [NG42] Motor Neurone Disease: Assessment and Management, 2016.
- [2] S.C. Bourke, et al., Effects of non-invasive ventilation on survival and quality of life in patients with amyotrophic lateral sclerosis: a randomised controlled trial, *Lancet Neurol.* 5 (2006) 140–147.
- [3] T. Aridegbe, R. Kandler, S.J. Walters, T. Walsh, P.J. Shaw, C.J. McDermott, The natural history of motor neuron disease: assessing the impact of specialist care, *Amyotroph. Lateral Scler. Front. Degener.* 14 (2013) 13–19.
- [4] H.W. Lee, J.W. Verlander, J.M. Bishop, M.E. Handlogten, K.H. Han, I.D. Weiner, Renal ammonia excretion in response to hypokalemia: effect of collecting duct-specific Rh C glycoprotein deletion, *Am. J. Physiol. Ren. Physiol.* 304 (2013) 410–421.
- [5] M. Feldman, N.M. Alvarez, M. Trevino, G.L. Weinsteing, Respiratory compensation to a primary metabolic alkalosis in humans, *Clin. Nephrol.* 78 (2012) 365–369.
- [6] J. Alvarez, R.B. Low, Acute respiratory arrest due to hypokalaemia, *Ann. Emerg. Med.* 17 (1988) 288–289.
- [7] B. Nand, S.K. Vohra, Hypokalaemic periodic paralysis: an unusual cause, *Hosp. Physician* 39 (2003) 59–63.
- [8] S. Agrawal, V. Bharti, M.N. Jain, P.D. Purkar, A. Verma, A.K. Deshpande, Sjögren's syndrome presenting with hypokalemic periodic paralysis, *J. Assoc. Phys. India.* 60 (2012) 55–56.
- [9] J.M. Poux, P. Peyronnet, Y. Le Meur, J.P. Favereau, J.P. Charnes, C. Leroux-Robert, Hypokalemic quadriplegia and respiratory arrest revealing primary Sjögren's syndrome, *Clin. Nephrol.* 37 (1992) 189–191.
- [10] R. Windsor, W. Petchey, Metabolic alkalosis in a patient with dyspnoea, *BMJ* 346 (2013) f2710.